

# Cataract FAQs and practice pearls for Successful Patient Management



As our patients get older, more and more will present with signs and symptoms of cataracts. But, these patients are not necessarily in their 60s and 70s. Practices with large myopic population, high number of patients with allergies taking inhaled steroids, and patients with significant exposure to sunlight, may be seeing younger patients who present with symptoms of changing vision, glare, diplopia, asthenopia, and decreased best corrected vision. These patients may be as young as 40 years old. They need to be evaluated for cataracts as well. Early cataract surgery equals early visual rehabilitation and better quality of life for these patients. The patients are also technology savvy, well-informed, and are often familiar with the latest advances in cataract surgery. They will ask questions and will be aware of their options much like our LASIK patients do. At Pacific Vision Institute, we provide all the patients with access to the most advanced, clinically-proven, evidence-based medicine and surgical expertise.

In this issue of eFocus, we go back to the basics and review the common cataract FAQs. We also outline postoperative medication regimen, share management pearls for patients with special considerations, and re-

view practice pearls for managing patients with cataracts.

## WHAT ARE THE RISK FACTORS FOR CATARACTS

- Age
- Smoking
- Sun exposure
- Myopia
- Diabetes
- Trauma or intraocular surgery
- Steroids – In a recent study published in *Ophthalmology*, inhaled corticosteroids increase patients' risk of developing nuclear sclerosis cataracts. Patients who use both inhaled and oral corticosteroids are at risk for developing both nuclear and subcapsular cataracts. The risk of cortical cataracts is not increased in steroid users.
- Diabetes, etc.

## CLASSIFICATION OF CATARACTS

Cataracts have been organized in to many different groups based on a number of factors. The chart below provides some examples of the various types of cataracts seen on examination.

	Example
Organized by AGE	Congenital cataract
	Juvenile onset cataract
	Senile Cataract
Organized by CAUSE	Traumatic Cataract
	Diabetic Cataract
	Steroid related cataract
Organized by LOCATION	Nuclear sclerotic cataract
	Cortical Cataract
	Posterior Subcapsular Cataract

## WHEN SHOULD CATARACT SURGERY BE PERFORMED

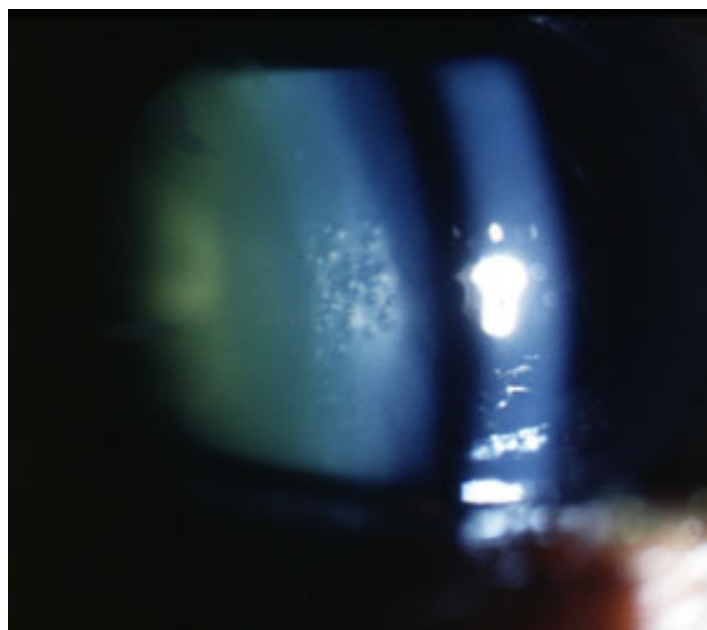
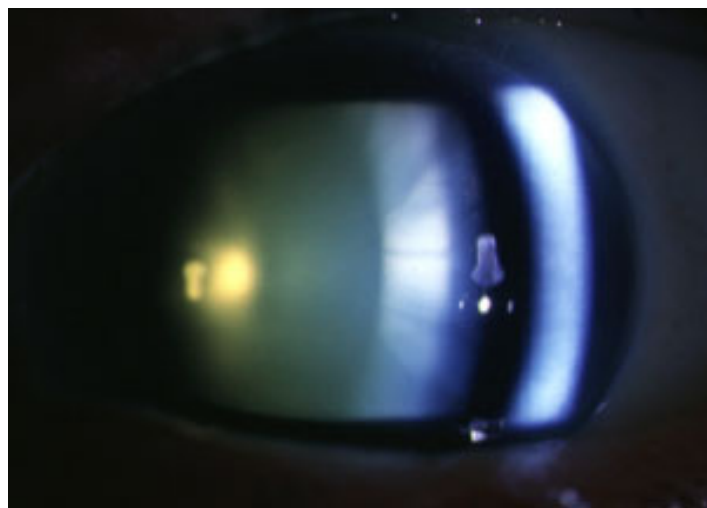
There is a common perception that cataract needs to be “ready” to be removed, that it needs to have “matured.” In fact, the denser the cataract, the harder it is to remove it and complications are more likely. Early cataracts are easier to remove, resulting in speedy recovery to good vision.

- Visual acuity is one metric by which to judge whether the cataract needs to be removed. Visual acuity of 20/40 or better is typically used as a guideline. Snellen chart acuity, however, is only a piece in the decision making process. Sometimes, it is actually a very minor piece. Lens changes associated with Snellen visual acuity as good as 20/20 can, in fact, be quite debilitating to patients under their normal living and working conditions. They may suffer from glare, reduced contrast sensitivity, significant anisometropia resulting in symptoms of asthenopia, rapidly changing refraction, and other symptoms that we need to be attuned to in order to guide patients toward cataract surgery. Figure 1 demonstrates lenticular changes that can impair function in patients whose Snellen acuity may be 20/20.
- Early cataract removal will restore patient’s quality of life and will be a significantly easier procedure for the patient than waiting until the cataract becomes very dense (Figure 2).

## HOW IS CATARACT SURGERY PERFORMED

Cataract surgery has come through major changes in the past 30 years. The main transition has been to small incision phaco-emulsification, clear cornea, topical anesthesia, with IOLs correcting refractive error. Figure 3 outlines evolution of cataract surgery from large incision to micro-incision surgery.

- Modern surgery is done in an out patient setting



**Figure 1.** 2+ nuclear sclerosis (top) and 2+ nuclear sclerosis with vacuoles (bottom) may test 20/20 on the Snellen visual acuity chart but may impair patient’s functioning due to changing refractive error, anisometropia, and glare.

under local anesthesia. Intravenous sedation is often given as well to help patients relax. Because experienced surgeons can perform most surgeries in less than fifteen minutes, patients are comfortable and there is no need for retrobulbar or peribulbar injections.

- Clear cornea incision is typically created. It is small (2-3 mm) and self-sealing without the need for sutures. The eye is comfortable with minimal conjunctival injection after the case. The cornea is typically clear with minimal edema, if any, at the incision site.
- Ultrasound energy is used to liquefy the cataract and it is removed through an ultra-thin tube.
- The IOL is typically placed in the capsular bag; the capsulorrhexis of the anterior capsule is round and symmetric.
- If astigmatism was managed with limbal relaxing

	Week 1	Week 2	Week 3	Week 4
<b>Pred Forte</b>	4x / day	4x / day	2x / day	1x/day until bottle finished
<b>Xibrom (double the dose on acular)</b>	2x / day	2x / day	2x / day	1x/day until bottle finished
<b>Zymar/ Vigamox/ Quixin</b>	4x / day	STOP	0	0

incisions (LRIs), these will be seen near the limbus. One or two may be seen. The arcs should be smooth, even, and closely approximated without gaping.

- Patients go home with a clear shield over the eye.

### WHAT ARE POSTOPERATIVE INSTRUCTIONS AND MEDICATIONS AFTER CATARACT SURGERY

Patients are placed on a regimen of post operative medications (Figure 4) including a topical steroid (Pred Forte), NSAID (Xibrom), and antibiotic (such as a 4th generation fluoroquinolone, i.e. Zymar, for example). Patients are provided with a detailed instruction sheet describing how the drops should be tapered over the next 4 weeks. Please see the chart for a summary of the medication taper.

### WHAT ARE POSTOPERATIVE INSTRUCTIONS AND MEDICATIONS AFTER CATARACT SURGERY

- Patients will use their eye drops for about a month.

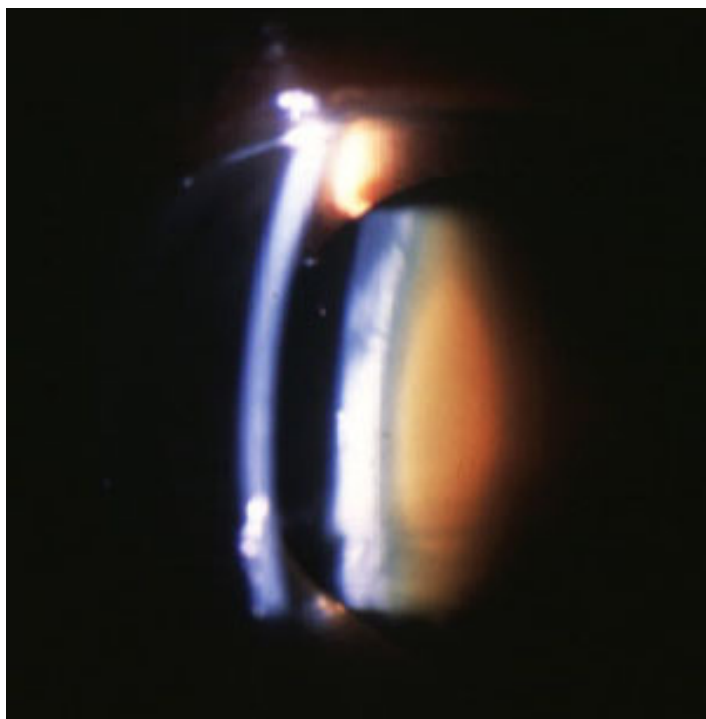


Figure 2. 3+ to 4+ nuclear sclerosis cataract

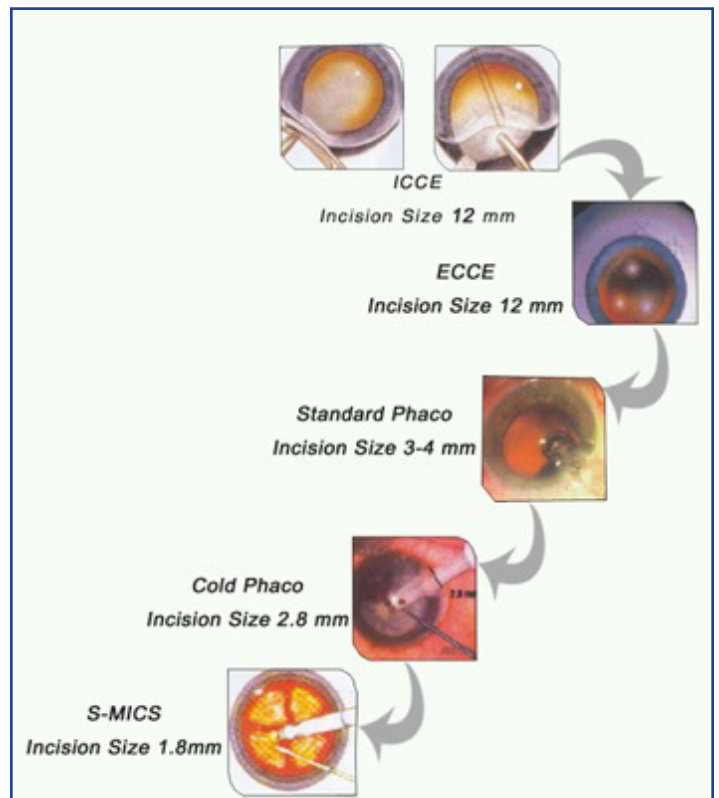


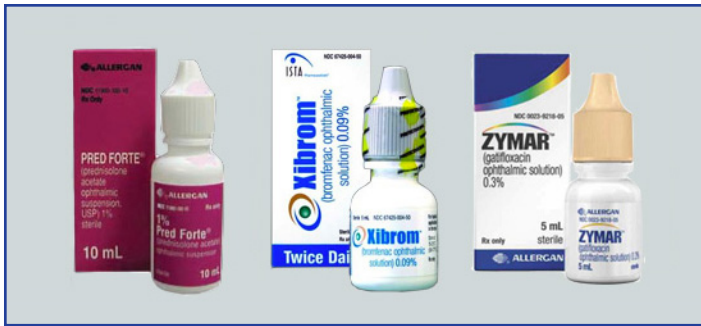Figure 3. Evolution of cataract surgery to modern, micro-incision procedure

- During the first week, patients are instructed to wear the shield to bed at night to protect their eyes while sleeping.
- When they are outdoors or in dusty environments, patients are told to wear sunglasses or glasses to prevent any trauma to the eye.
- Patients should avoid bending over, heavy lifting (over 10 lbs), or straining for one week after the procedure.
- Patients should also avoid submerging the eye into water, and swimming underwater is prohibited for about 6 weeks after cataract extraction surgery.

### WHEN SHOULD THE PATIENT BE SEEN POSTOPERATIVELY AND WHAT TO LOOK FOR AT EACH EXAM

Routine post-operative visits should be scheduled one day, one week, and one month after surgery.

- ONE DAY EXAM



**Figure 4.** Postoperative drops are Pred Forte (left), Xibrom (center), and fluoroquinolone such as Zymar (right), for example.

- Examine incision to make sure it is sealed (Seidel negative, anterior chamber is formed)
- Look at the cornea. Mild corneal edema is not unusual, especially at the wound where small microcysts may be seen. Patients should be reassured that corneal swelling is expected and consequently vision may be blurry for the first several weeks after surgery
- Check IOP to make sure it's normal (Typically between 10 and 25 mmHg by Goldmann)
- Look at the IOL to make sure it is situated in the correct location.
- Evaluate anterior chamber for cell and flare. Mild inflammation (less than 2+ cell) is normal.
- Reinforce to the patient the importance of compliance with the post-operative medication regimen to prevent infection and reduce inflammation.

#### • ONE WEEK EXAM

- Refraction can provide helpful information about how the patient is adapting to the new intraocular lens. Patients should report improving vision as the corneal edema subsides.
- Examine incision. The incision should be closed (no fluorescein staining).
- Look at the cornea. It should be almost clear.
- Check IOP to make sure it's normal (Typically between 10 and 21 mmHg by Goldmann)
- Evaluate anterior chamber for cell and flare. The inflammation should be decreased from the one day visit. Persistent large amounts of anterior chamber reaction, fibrin, or hypopyon formation are ominous warning signs for endophthalmitis. Patients with this finding must be evaluated by their surgeon immediately. Similarly, cataract surgery is normally a painless procedure and complains of pain should be investigated carefully.

#### • FOUR WEEK EXAM

- A final refraction can be performed on patients at this time. The cornea should be well healed and the anterior chamber should be free of cells or inflammation.
- Patients with monofocal IOLs without intraoperative astigmatism management can be prescribed glasses for far and near.
- Patients with toric IOLs +/- LRIs for astigmatism management typically do well with readers only, unless monovision was targeted.
- Patients with presbyopic IOLs and LRIs, may not need glasses for any activities.
- This is the visit where laser vision correction touch ups can be discussed as well. During pre-operative assessment, the surgeon would have determined if the patient's cornea and ocular surface are suitable to future corneal refractive surgery. If so, then laser vision correction touch up can be performed, if necessary. This is typically performed at 3 months postoperatively. YAG laser capsulotomy may need to be performed prior to LVC touch up.
- Incision should be healed and anterior chamber should be free of cells
- Dilated examination performed at this visit to examine posterior capsule and retina.

#### WHAT ARE THE RESULTS OF CATARACT SURGERY

Patients can be reassured that in the hands of experienced surgeons, modern cataract surgery is one of the most successful procedures in the world today.

- In the absence of other eye diseases, the vision should be 20/20.
- Dependence on glasses can be decreased by using special intraocular lenses, intraoperative limbal relaxing incisions, and/or postoperative laser vision correction utilized in advanced surgical practices focused on refractive cataract surgery.

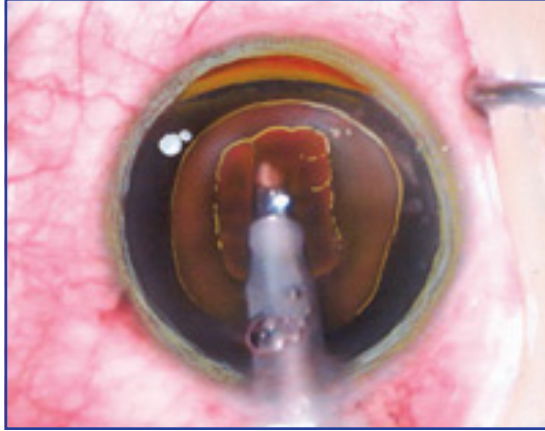
#### WHAT IS THE VISUAL RECOVERY LIKE AFTER CATARACT SURGERY

After surgery, most patients should be able to see right away, although the vision will be somewhat blurry. The vision should improve over the subsequent several weeks. Patients may experience mild foreign body sensation initially, but any complaint of pain should be investigated. There should be no pain after cataract surgery.



## MANAGING PATIENTS WITH SPECIAL CONSIDERATIONS

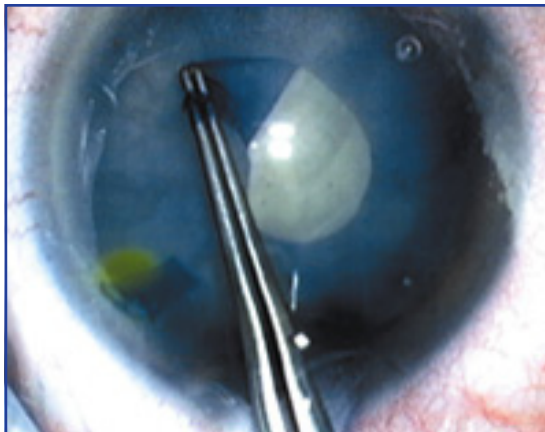
Special considerations are given to patients with the conditions described below. These are patients where extra precautions need to be taken and special surgical expertise needs to be applied to deliver outstanding results.



**Figure 5A.** Special considerations in cataract surgery. Technique for removing hard nucleus may involve making a narrow trough with ultrasound instrument to facilitate breaking it up into fragments;

### • HARD NUCLEUS (Figure 5A)

An extremely hard cataract will require extensive amounts of ultrasound energy to emulsify which can challenge corneal endothelium, especially in patients with pre existing conditions such as Fuchs' dystrophy. In addition, since very hard cataracts are usually found patients who undergo the procedure at a much older age, their corneas may also be at higher risk from endothelial cell loss over time. These cases must be approached with caution, the best surgical technology and techniques must be used, and extreme care must be taken by the surgeon to perform the procedure successfully. Improvements in viscoelastics have also allowed surgeons to better protect the cornea during these challenging cases. The best advice – don't let the

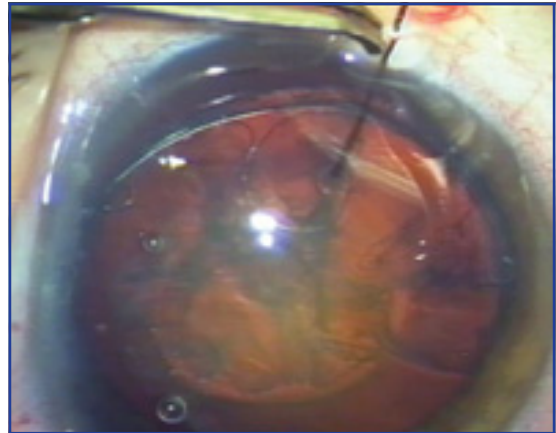


**Figure 5B.** Special considerations in cataract surgery. Capsule staining may be used in patients with white cataract to visualize the capsule and to facilitate capsulorrhexis

patients wait until their nucleus becomes so hard that it's difficult to remove it. Early cataract surgery in qualified patients prevents a difficult case.

### • WHITE CATARACT (Figure 5B)

More severe cataracts may also become completely opaque or even white, in the case of hypermature cataracts. The lack of a red reflex in these patients prevents visualization of the anterior capsule during the capsulorrhexis. Fortunately the increasing availability of capsule stains has provided a reliable method to see the anterior capsule and safely proceed despite a minimal or absent red reflex.

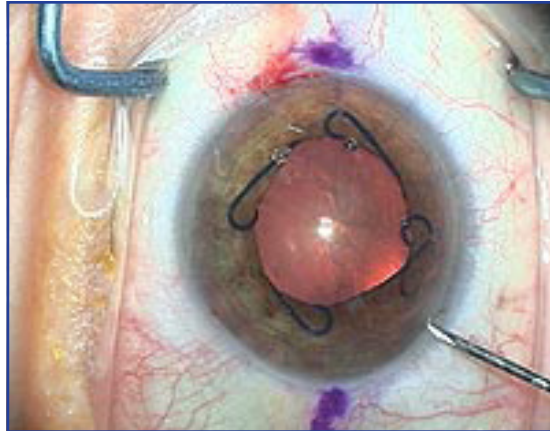


**Figure 5C.** Capsular tension ring can be inserted into the capsule to increase capsular stability in patients with zonular dialysis due to pseudoexfoliation

### • PSEUDOEXFOLIATION (Figure 5C)

In these patients, a fibrinous material is found in concentric rings on the anterior capsular surface. The posterior surface of the iris is thought to rub this material off of a "shedding" capsule, producing these rings. This exfoliated material can clog the trabecular meshwork causing high pressure and glaucoma. More significantly, patients also experience varying degrees of lens zonule loss, possibly caused by the material released from the lens capsule. In severe cases, enough lens zonules are lost to disrupt the support structure of the lens, and risk lens dislocation or loss into the vitreous. In addition the loss of zonules creates abnormal zones of tension on the capsule increasing the risk of capsule tears during the capsulorrhexis procedure. Because of the high risk of complication in patients with pseudoexfoliation, surgeons have devised new methods for better control of the lens in these difficult situations. Heavy viscoelastics have been developed to help spread tension more evenly across the capsule during the rhexis. Capsular tension rings (CTR's) were created to support the lens capsule and distribute tension to the remain-

ing lens zonules during the cataract removal. Careful implementation of these advanced techniques has resulted in dramatically fewer complications and improved patient outcomes.



**Figure 5D.** Malyugin pupil expansion device creates a large and stable pupil in a patient with IFIS.

● **INTAOPERATIVE FLOPPY IRIS SYNDROME (IFIS, Figure 5D)**

Finally, one of the most recently discovered risk factors in modern cataract surgery has been the rapid proliferation of medications used to treat benign prostatic hypertrophy, specifically tamsulosin (or Flomax). While remarkably effective in improving patients' urinary symptoms, a number of medications in this class of drugs have been found to inhibit specific receptors of the pupillary dilator muscle, specifically alpha-1 receptor. Clinically, the iris may demonstrate poor or slow dilation on examination. During intra-ocular surgery in these patients, not only is the view of the lens obscured by poor dilation, but the iris is often unstable with frequent prolapse out of the wound. This finding led the discovery team to name the condition Intraoperative Floppy Iris Syndrome (or IFIS). No dose response relationship has been discovered and some patients have been found to exhibit IFIS after as little as one week of Flomax use. Interestingly, discontinuation of the medication will usually have little effect on the iris tone. It is, therefore, important to ask patients not only about their current medication use, but also what they used in the past. Experienced surgeons can identify patients at risk, and have developed new techniques to stabilize the iris.

- Modern viscoelastic materials can be employed to help hold the iris in place.
- Intracameral lidocaine with epinephrine can be used to maintain pupillary dilation
- If additional stability is required, iris hooks or

Malyugin ring can be deployed to dilate the pupil and prevent iris prolapse.


- Improved surgical techniques and blades allow surgeons to create better sealing wounds as well to protect intraocular tissues during surgery.

Despite these interesting challenges confronting modern cataract surgeons, constantly improving technology and advanced techniques will allow patients to achieve the excellent outcomes they demand ■

## Pacific Vision Institute Annual Optometric CE Program

- 07/23/09 PVI Grand Rounds  
Dry eye management
- 08/27/09 PVI Grand Rounds  
Antibiotics and anti-inflammatory medications
- 09/24/09 PVI Grand Rounds  
Cataract co-management considerations in patients with previous corneal refractive surgery

### Sight Gags by Scott Lee, O.D.



Scott F. Lee, O.D., Editor-in-Chief, eFocus.  
Contact information: drlee@pacificvision.org, 415.922.9500